



AT THE FOREFRONT  
**UChicago**  
**Medicine**

Comprehensive  
Cancer Center  
**Silver Cross**

## Patient Case Study: Simple Bolus - Basal Cell Carcinoma

University of Chicago Comprehensive Cancer Center at Silver Cross Hospital, New Lenox, IL, USA

### Overview

Adaptiiv Medical Technologies Inc. (Adaptiiv) provides cancer centers with the hardware, software, and materials to design and 3D print custom RT accessories. This patient case demonstrates the application of our technology used in clinical radiation oncology through the creation of simple bolus for electron radiotherapy. This case is a great example of how Adaptiiv's software can be effectively used to design a custom-shaped 3D printed bolus for the nose.

### Patient History

A female patient was treated at the University of Chicago Comprehensive Cancer Center at Silver Cross Hospital for the management of basal cell carcinoma after Mohs micrographic surgery to the right nose. Her treatment options included a skin graft procedure or radiation therapy, with the patient electing for the latter.

### Description

This case study demonstrates a clinical application of 3D printing in clinical radiation oncology through the creation of bolus to treat a female patient with basal cell carcinoma of the right nose. The plan was to do a mini CT scan first to create a 3D printed bolus, and then do a full CT simulation with the printed bolus on the patient's right nose and treat her disease with one electron field. The application of bolus was necessary to deliver the prescribed dose to the skin surface.

3D printing was used to create a custom-shaped bolus to follow surface irregularities around the nose and fill in the air space in the right nostril (see Figure 1). For comparison, the patient was also scanned with the wax bolus (see Figure 2). Adaptiiv software was used to determine the shape of the 3D bolus.

## Fabrication and Treatment

The bolus was designed in order to achieve optimal dose distribution to the small target volume in the right nose and spare tissues distal to it. The width of the bolus was intended to cover the GTV with 20mm margins. Uniform thickness of 7mm was used. DICOM images of the bolus were converted to a stereolithography (STL) file. The end product was fabricated with the Airwolf 3D AXIOM 20 M printer, using Cheetah™ by NinjaTek™ TPU filament – both the printer and filament are fully validated for use with Adaptiiv's solution. The printing duration was approximately 3 hours. The patient received 45Gy over 15 fractions @ 6 MeV.

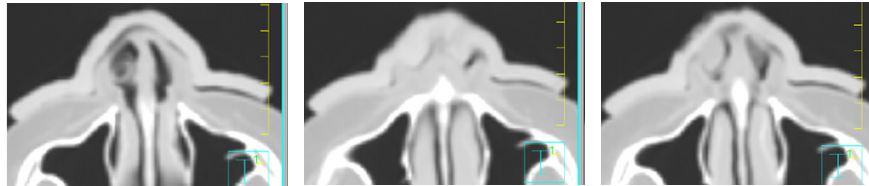


Figure 1.  
Axial CT slices superior-inferior of the right nose with 3D printed bolus.

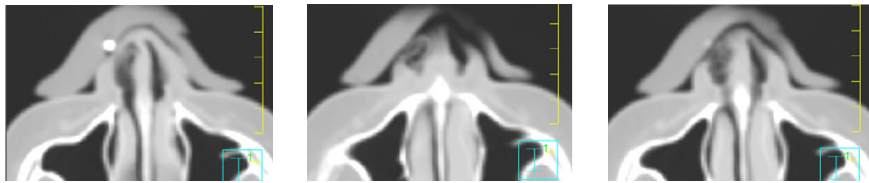


Figure 2.  
Corresponding CT slices superior-inferior of the right nose with wax bolus.

## Results / Findings

The custom bolus was designed in Adaptiiv software and fit perfectly. Based on the treatment planning CT, the size of the largest air gap at the interface of the 3D printed bolus was 2mm. An acceptable treatment plan was obtained (90% isodose to 100% of GTV) (see Figure 3). The 3D printed bolus was rigid and could be reproducibly placed at the times of planning CT and daily treatments, without causing discomfort.

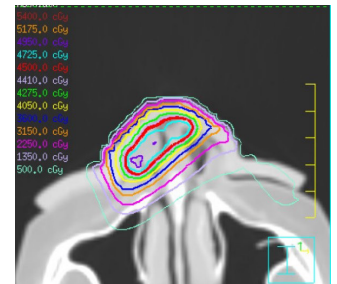


Figure 3.  
Acceptable treatment plan with the 3D printed bolus to the right nose.

## Summary

1. The Adaptiiv software solution was used to design a patient-specific bolus with superior fit compared to wax bolus.
2. 3D printing was used to create a custom-shaped bolus to follow surface irregularities around the nose and fill in the air space, reducing air gaps to no larger than 2mm.
3. An acceptable treatment plan was obtained (90% isodose to 100% of GTV).
4. The 3D printed bolus could be reproducibly placed at the times of planning CT and daily treatments, improving patient experience and comfort.